

Free Hand Technique for Lateral Mass Screws Insertion: A Safe, Accurate, and Simple Procedure for Posterior Cervical Spine Fixation

Mahmoud Wahdan, Ahmed Saleh, Mohammed Mourad*

Department of Neurosurgery, Faculty of Medicine, Benha University, Egypt

*Corresponding author: Mohammed Mourad, Mobile: (+20)01558445071, Email: morademam@yahoo.de.

ABSTRACT

Background: In the surgical treatment of disorders of the subaxial cervical spine, posterior cervical fixation procedures are routine. The posterior cervical spine is often fixed with lateral mass screws. It is regarded an ideal strategy for cervical stability repair following posterior cervical decompression. The aim of the study was to evaluate the efficacy of the free hand technique defining the optimum trajectory to insert safely lateral mass screws into the cervical spine. **Patients and methods:** A total of 30 patients with cervical canal stenosis and multiple disc prolapse were operated on in Benha university hospitals with 172 lateral mass screws inserted using the freehand technique through a midline posterior approach. Post-operative clinical assessment as well as CT scans were utilized to evaluate how well the free-hand method worked and whether it was safe to use.

Results: One hundred seventy-two screws were inserted in 30 patients with an average of 6 screws per case. After the surgery, a CT scan was performed to check the screw placement and trajectory. 172 screws inserted easily and correctly with no complications while 8 screws were failed to be inserted because of a violation of the lateral mass during the insertion. No vascular or neurological complications were encountered in the postoperative period or the follow-up period. **Conclusion:** The freehand technique is a safe and reliable surgical technique to insert lateral mass screws with a very good post-operative purchase and a high level of safety and feasibility. Neurovascular complications are usually avoidable when using this trajectory.

Keywords: Posterior cervical spine fixation, Free hand technique, Lateral mass screws insertion, Cervical canal stenosis.

INTRODUCTION

The cervical spine, which has a natural lordotic curve, is made up of seven cervical vertebrae held together by intervertebral discs and a web of ligaments. The cervical spine is more prone to degenerative and traumatic illnesses because of its greater mobility compared to the dorsal and lumbar sections of the spine ⁽¹⁾.

When viewed from behind, the bony junction between the superior and inferior articular processes forms a quadrilateral area called the lateral mass. This area is separated from the lamina medially by a sulcus, and it lies lateral to the lamina and between the borders of the superior and inferior facets (the medial facet line). The pedicle attaches the lateral mass to the vertebral body ⁽²⁾.

Various screws such as the transarticular screw, pedicle screw, as well as lateral mass screw are selected commonly for posterior cervical fixation techniques to treat the degenerative as well as traumatic diseases of the subaxial cervical spine. For the best results in reestablishing cervical stability after a posterior cervical laminectomy, lateral mass screw fixation has replaced previous methods. Lateral mass screws, unlike posterior wiring, do not depend on the posterior elements. Rods system with lateral mass screws can be used effectively to restore normal curvatures, especially in degenerative spondylosis where the rods can be contoured besides the polyaxiality feature of the screws which solves previous alignment problems ⁽³⁾.

Many attempts had been done to fix the posterior cervical spine; **Harda** ⁽³⁾ in 1891 introduced wiring of the spinous process, which was modified later on by

Rogers ⁽⁴⁾ in 1942 to figure-of-eight wiring. The triple wiring technique then was described by **Bohlman** ⁽⁵⁾.

Roy-Camille et al. ⁽⁶⁾ in the early 1980s, Presented the idea of lateral mass fixation. **Grob and Magerl** ⁽⁷⁾ made some adjustments, most notably to the drilling trajectory of the divergently oriented lateral masses.

The advantage of lateral mass screwing over other fixation methods is that the lateral mass can be screwed without the need for intraoperative fluoroscopic control, making the procedure quick, easy, and successful ⁽⁸⁾. Because of these benefits, posterior cervical fixation with this technique is among the most widely used methods in the world ⁽⁹⁾.

The aim of the study was to evaluate the efficacy of the free hand technique defining the optimum trajectory to insert safely lateral mass screws into the cervical spine.

PATIENTS AND METHODS

A total of 30 patients with cervical canal stenosis and multiple disc prolapse were operated upon in Benha university hospitals with 172 lateral mass screws inserted with freehand technique through a midline posterior approach. Post-operative CT scans were used to assess the accuracy and safety of the free hand technique .

The surgical technique:

Under general anesthesia, we placed the patient in the prone position (Figure 1) with the neck should be held in a neutral posture with the help of a basic headrest or the Mayfield 3 pins skull fixation, with the arc of the Mayfield head holder perpendicular to the floor to prevent fusion in rotation.

An adhesive tape is pulled over the shoulders to stitch them off thus that the lower subaxial spine is more easily seen.

A typical posterior midline incision is used to expose the targeted levels where C2 is used always as a fixed anatomical landmark to count the levels. We prefer to extend the exposure of the field for at least one level beneath the bottom of the target level, which allows for greater freedom in adjusting and directing the lower screws.

After full exposure to the spinous processes and the laminae, we go more laterally in order to outline the facet joint and the outer limits of the lateral mass.

Unnecessary further Lateral dissection is advised to be avoided to reduce bleeding as well as postoperative chronic neck pain. Facet preparation is an important step where all soft tissue, For the facets to

be clearly defined and for the polyaxial screw heads to be able to rotate, osteophytes and other bone growths must be removed. Separated into four sections, the lateral bulk is seen here. To locate the center of the lateral mass, a cross is drawn using monopolar coagulation.

The bone is decorticated with a 2-mm high-speed drill at the entry point, which is 1ml medial and below the central point of the lateral mass. To avoid damaging the lateral mass's posterior cortex, the first hole's course should be perpendicular. On the other hand, it's best not to get things started by heading upwards and laterally; this is because the cortical bone of the lateral mass is rather little, and starting in this direction will inevitably result in a violation of the superior cortex of the lateral mass.

To avoid iatrogenic cord trauma, it is important to avoid using force when making entry holes. Since it's important to remember that the cord is already damaged.

After the creation of the hole, the drill handle is redirected towards the “safe quadrant”, located upward and lateral ventral corner with no fluoroscopic guidance .

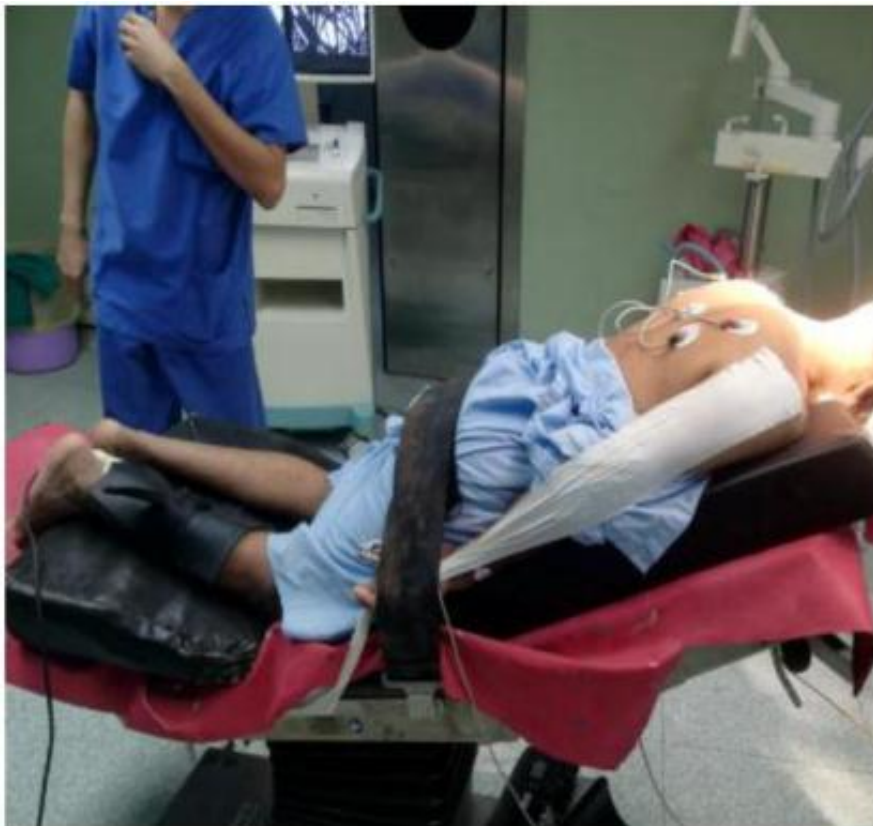

Figure (1): Position of the patient (Concord position).

Matching with Deen *et al.* (10) we guided the trajectory simply by two anatomical landmarks:

1. By inserting the tip of a straight instrument into the gap between the facet joints, we may determine the craniocaudal trajectory's angle. This allows one to pinpoint the dorsoventral angulation. The angle is 20–30 degrees off the horizontal, and it points directly upward in parallel with the superior facet joint.
2. The spinous process which is used as the second anatomical guiding structure to guide the angulation of the lateral trajectory: Throughout the entire operation of drilling in that trajectory, the screw assembly is slanted medially to rest on the tip of the spinous process of the spine. When operating from the contralateral side, directing the drill by touching the spinous process of the vertebra below is easier. If the surgeon performs a useful trich, in which the tip of the spinous process is removed, he or she will have better control of the drill and achieve more accurate results.

A probe is introduced to the already done tract before insertion of the screw to check the competency of all lateral mass walls. In which the screw's point should never extend beyond the back quarter of a vertebra. Thereafter, polyaxial screws with diameters between 12 and 16 mm (often 3.5 or 4.0 mm) are installed. Rods were bent to fit the shape of the cervical spine and then implanted into the vertebrae. To lock in the screws and the rods, a dynamometric tool is used to insert and tighten a head nut (Fig. 2). Suturing the skin over a suction drain is the final step in wound closure after the muscle layers have been sutured in different planes using resorbable sutures.

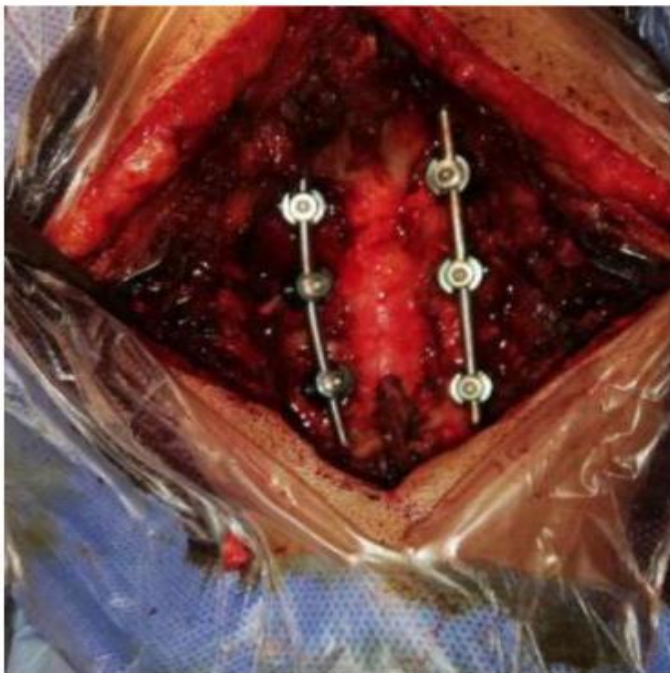


Figure (2): Intraoperative image of the exposed cervical spine posterior with 6 lateral mass screws and rod system associated with laminectomy to

decompress and fix cervical spine in 55 years old myelopathic female.

Ethical approval

The study was approved by the Ethics Board of Benha University and an informed written consent was taken from each participant in the study. This work has been carried out in accordance with The Code of Ethics of the World Medical Association (Declaration of Helsinki) for studies involving humans.

Statistical analysis

The collected data were coded, processed and analyzed using the SPSS (Statistical Package for Social Sciences) version 22 for Windows® (IBM SPSS Inc, Chicago, IL, USA).

RESULTS

A total of 30 patients who had lateral mass screws placed posteriorly in the subaxial cervical spine were chosen for this study; Patients' ages ranged from 27 to 79, with a mean of 54.26 (there were 19 male and 11 female patients). Our research found a wide range in symptom duration, from 8 weeks to 2 years, with a mean of 11.9 months.

In this study, all patients were presented with neck pain as well as brachialgia where (21 patients) were presented with bilateral brachialgia and the other (9 patients) have unilateral brachialgia. Numbness in hands was present in (22 patients) while sphincteric manifestations were documented in (15 patients) (Table 1). Neurological examination reveals a motor weakness in the upper limb in (19 patients), hyperreflexia in the upper limb in (20 patients), pathological reflexes (+ve Hoffmann) in (23 patients), and gait disturbance in (22 patients) (Table 2).

Table (1): Preoperative clinical presentations of all patients.

Symptoms	Number of patients
Neck pain	30
Bilateral brachialgia	21
Unilateral brachialgia	9
Numbness in hands	22
Sphincteric manifestations	15

Table (2): Preoperative neurological examination of all patients.

Signs	Number of patients
Motor weakness in the upper limb	19
Hyperreflexia in the upper limb	20
Pathological reflexes	23
Gait disturbance	22

A total of 172 screws inserted easily and correctly with no complications while 8 screws were failed to be inserted because of a violation of the lateral mass

during the insertion an example is illustrated in (Figure 3). Intra-operatively we did not document either neural or vascular injuries. However, in some cases, there was a lot of bleeding from the vertebral venous plexus which prolongs the surgery to control such bleeding .

Postoperatively, we were unable to find any signs of neurological decline or injury, including those caused by a vertebral artery stroke or damaged nerve roots.

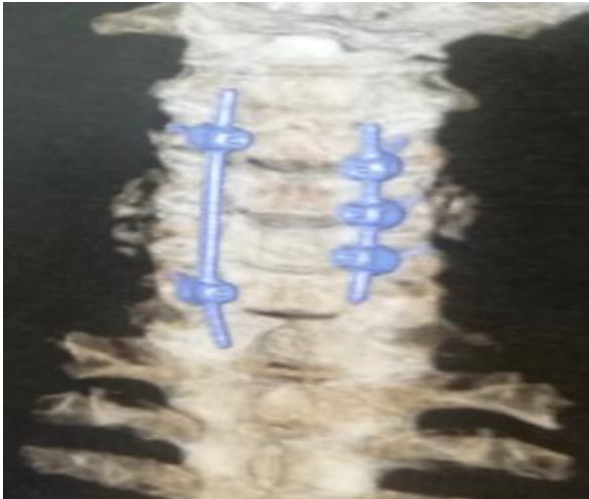


Figure (3): Postoperative CT 3D of the cervical spine posterior view showing failure of insertion of 2 screws due to violation of the lateral mass at those 2 levels while good placement of the other lateral mass screws. Rod system associated with laminectomy to decompress and fix cervical spine in 53 years old myelopathic female.

Postoperative assessment of the motor power revealed that the motor weakness showed total improvement in 10 patients, better than preoperative in 5 patients, and no improvement in 4 patients. Twenty-five patients reported improvement in brachialgia after surgery, while twenty-five reported relief in neck pain. Numbness improved totally in (10 patients) and partially in the other 12 patients. No worsening of postoperative symptoms was seen; 18 patients showed improvement in gait heaviness and 13 patients showed improvement in sphincteric manifestation (Table 3).

Table (3): Postoperative outcome.

Improvement in symptoms and signs	Number of patients
Motor weakness	15 out of 19
Brachialgia	25 out of 30
Neck pain	20 out of 30
Numbness in hands	22 out of 22
Gait disturbance	18 out of 22
Sphincteric manifestation	13 out of 15

Six cases with only superficial wound infection which doesn't extend to deep regions were encountered. Except for one patient who required revision and improved clinically after revision, postoperative CT scans of patients with persisting C5 palsy and

appropriate screw positioning indicated no violation by screws of the C4-C5 neural foramen.

Patients were followed up with for an average of 14 months (range, 4-35 months). Follow-up radiologic imaging document that the optimum position of the screws with good bony fusion in all patients except one (99.1%). (Figures 4-7) Subjective postoperative satisfaction was analyzed based on MacNab classification into grades of "excellent" (no pain), "good," "fair," and "poor" (unchanged or worse)⁽¹¹⁾.

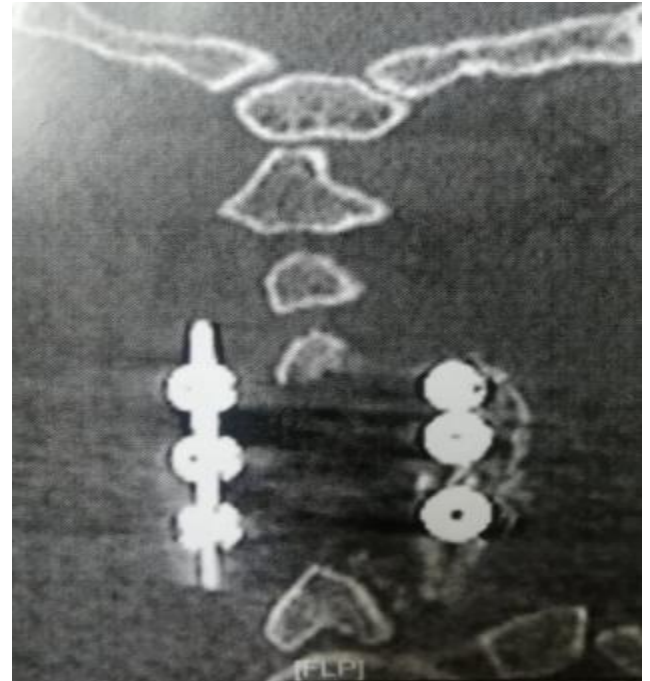


Figure (4): Postoperative CT cervical spine (coronal view) showing 6 lateral mass screws with the rod system accompanied with laminectomy to decompress and fix cervical spine in 55 years old myelopathic female.

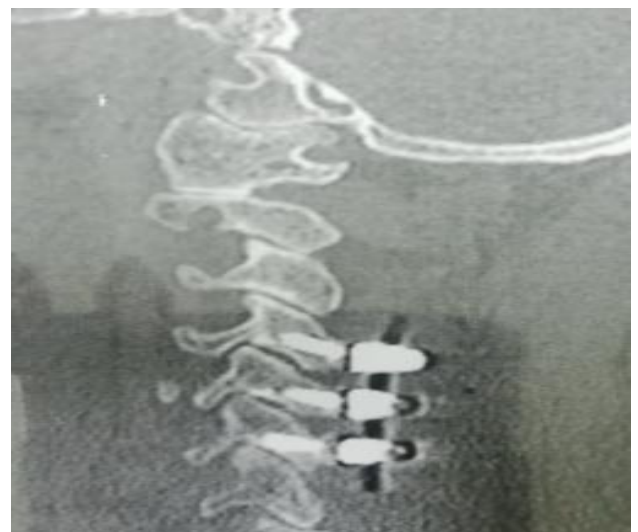

Figure (5): Postoperative CT cervical spine posterior coronal view showing lateral mass screws with the rod system associated with laminectomy to decompress cervical spine in 66 years old myelopathic female.

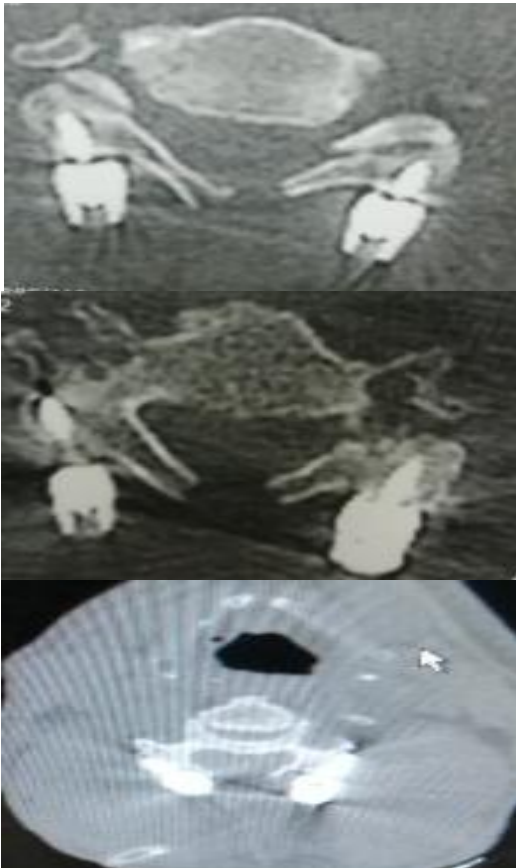


Figure (6): Postoperative CT cervical spine axial views at different levels showing lateral mass screws trajectory along with laminectomy to decompress cervical spine in different patients.

The functional outcome according to McNab criteria was documented as follows; 15 patients showing excellent, 11 patients showing good, and 4 patients showing a fair outcome. (Table 4).

Table (4): Postoperative functional outcome.

McNab Criteria	Number of patients
Excellent	15
Good	11
Fair	4

DISCUSSION

When the posterior parts are missing, the lateral mass fixing procedure has risen to prominence. As part of this procedure, polyaxial screws are inserted into the lateral masses of the subaxial cervical spine and the pedicle of C2, and a rod system is then linked to these two bones⁽¹²⁾.

In comparison to cervical pedicle screws which are used as an alternative fixation technique; lateral mass screws are considered a safe procedure with a higher success rate and low comorbidities. The failure rate in early studies was documented as high screw-plate structures for patients as opposed to the more recent polyaxial screw-rod systems. For the most part, modern polyaxial screw-rod systems are more restricted and, in essence, avoid screw pullout, which can increase stability⁽¹³⁾.

A variety of screw entry locations and orientations have been documented to facilitate this kind of operation. The middle of the lateral mass is chosen as the entry location for the screw, and the screw is angled 10 degrees outward from being perpendicular to the posterior portion of the cervical spine⁽¹⁴⁾.

While Heller *et al.*⁽¹⁵⁾ mentioned that the target point is located 2–3mm medial and above the midpoint of the lateral mass with 30° angulation upward and 25° laterally. Anderson *et al.*⁽¹⁶⁾ advised starting drilling at a point located 1mm medial to the midpoint of the lateral mass while the screw should be angled at 30°–40° upward and 10° lateral. An and Coppes⁽¹⁷⁾ described an angle of 15°–18° upward and 30°–33° laterally as a trajectory, and moving 1mm medially from the center of the lateral bulk as a starting point. To greatly reduce the risk of neurovascular injury, Pait *et al.*⁽¹⁸⁾ devised a four-quadrant system for the lateral mass, with the upper outer quadrant serving as the trajectory target for the screw direction.

Our results match the study conducted by Kim *et al.*⁽¹⁹⁾ in which thirty-two men and seven women, ranging in age from 27 to 79 years old (mean age, 54.26 years old), all received posterior cervical lateral mass screw fixation.

We present evidence that the prognosis deteriorates with increasing age, either clinically or radiologically matching Epstein's study which documents that the cutoff age at the time of operation




Figure (7): Postoperative CT 3D of the cervical spine posterior (a) and lateral (b) views showing perfectly placed lateral mass screws, inserted in 56 and 62 years old patients respectively through free hand technique.

is 72 years; age above this limit is considered one of the bad prognostic factors⁽²⁰⁾.

Regarding The duration of symptoms in our series which ranged from 1 week to 2 years; in the study published in May 2008 by **Fehlings et al.**⁽²¹⁾, it was concluded that there is no correlation between the duration of symptoms and the surgical outcome.

On the contrary, to that, we found that the duration of symptoms can affect negatively the outcome, especially in cervical spondylotic myelopathy. In our study, the main pathology was cervical myelopathy due to cervical canal stenosis reflecting the higher incidence of degenerative cervical spondylosis in our country due to the nature of heavy work.

Our results regarding postoperative improvement of brachialgia, numbness, gait heaviness, and sphincteric manifestation agreed with the study conducted by **Houten and Cooper**⁽²²⁾ who treatment for spondylotic degenerative cervical disease included a laminectomy from C3 to C7 followed by rapid stabilization with a lateral mass fixation.

None of our patients showed any deterioration of their achieved functional grade after a 6-month follow-up which confirms the important role of lateral mass screws in cervical fixation eliminating the dynamic compressive factors, which stand as the main pathological factor leading to progressive neurological deterioration in patients with cervical spondylotic myelopathy. There was no increased morbidity due to added instrumentation.

In conclusion, the freehand technique is a safe and reliable surgical technique to insert lateral mass screws with a very good post-operative purchase and a high level of safety and feasibility. Neurovascular complications are usually avoidable when using this trajectory.

Financial support and sponsorship: Nil.

Conflict of interest: Nil.

REFERENCES

1. **Kanwar R, Delasobera B, Hudson K et al. (2015):** Emergency department evaluation and treatment of cervical spine injuries. *Emerg Med Clin North Am.*, 33(2):241-82.
2. **Jónsson H, Rauschnig W (1994):** Anatomical and morphometric studies in posterior cervical spinal screw-plate systems. *J Spinal Disord.*, 7:429-38.
3. **Hadra B (2007):** Wiring of the vertebrae as a means of immobilization in fracture and Potts' disease, 1981. *Clin Orthop Relat Res.*, 460:11-3.
4. **Rogers W (1942):** Treatment of fracture dislocation of cervical spine. *J Bone Joint Surg Am.*, 24:245-58.
5. **Bohlman H (1985):** Surgical management of cervical spine fractures and dislocations. *Instr Course Lect.*, 34:163-87.
6. **Roy-Camille R, Saillant G, Laville C et al. (1992):** Treatment of lower cervical spine injuries—C3 to C7. *Spine*, 17(10): 442-6.
7. **Grob D, Magerl F (1987):** Dorsal spondylolisthesis of the cervical spine using a hooked plate. *Orthopade.*, 16(1):55-61.
8. **Roche S, de Freitas D, Lenahan B et al. (2006):** Posterior cervical screw placement without image guidance: a safe and reliable practice. *J Spinal Disord Tech.*, 19(6):383-8.
9. **Deen H, Brich B, Wharen R et al. (2003):** Lateral mass screw-rod fixation of the cervical spine: a prospective clinical series with 1-year follow-up. *Spine J.*, 3(6):489-95.
10. **Mohi Eldin M, Hassan A (2017):** Free hand technique of cervical lateral mass screw fixation. *J Craniovertebr Junction Spine.*, 8(2):113-8.
11. **MacNab I (1971):** Negative disc exploration: an analysis of the cause of nerve root involvement in sixty-eight patients. *J Bone Jt Surg.*, 53:891-903.
12. **Sekhon L (2006):** Posterior cervical decompression and fusion for circumferential spondylotic cervical stenosis: review of 50 consecutive cases. *J Clin Neurosci.*, 13:23-30.
13. **Heller J, Estes B, Zaouali M et al. (1996):** Biomechanical study of screws in the lateral masses: variables affecting pull-out resistance. *J Bone Joint Surg Am.*, 78:1315-21.
14. **Roy-Camille R, Gaillant G, Bertreaux D (1979):** Early management of spinal injuries. In: McKibben B, editor. *Recent advances orthopedics*. Edinburgh: Churchill - Livingstone. pp. 57-87. Available at: <https://cir.nii.ac.jp/crid/1573668925761160960>
15. **Heller J, Silcox D, Sutterlin C (1995):** Complications of posterior cervical plating. *Spine*, 20:2442-8.
16. **Anderson P, Henley M, Grady M et al. (1991):** Posterior cervical arthrodesis with AO reconstruction plates and bone graft. *Spine*, 16:72-79.
17. **An H, Coppes M (1997):** Posterior cervical fixation for fracture and degenerative disc disease. *Clin Orthop Relat Res.*, 335:101-11.
18. **Pait T, McAllister P, Kaufman H (1995):** Quadrant anatomy of the articular pillars (lateral cervical mass) of the cervical spine. *J Neurosurg.*, 82:1011-4.
19. **Kim S, Seo W, Kim K et al. (2012):** Clinical outcome of modified cervical lateral mass screw fixation technique. *J Korean Neurosurg Soc.*, 52:114-9.
20. **Epstein N (1999):** Laminectomy with posterior wiring and fusion for cervical ossification of the posterior longitudinal ligament, spondylosis, and ossification of the yellow ligament, stenosis, and instability: a study of 5 patients. *J Spinal Disord.*, 12:461-6.
21. **Fehlings M, Kopjar B, Massicotte E et al. (2008):** The impact of duration of symptoms on the outcomes of surgical management of cervical spondylotic myelopathy: analysis of a prospective multicenter study. *Neurosurgery*, 62:1-163.
22. **Houten J, Cooper P (2003):** Laminectomy and posterior cervical plating for multilevel cervical spondylotic myelopathy and ossification of the posterior longitudinal ligament: effects on cervical alignment, spinal cord compression, and neurological outcome. *Spine*, 30: 2414-9.